

Lymphedema and lipedema

Lipedema	Lymphedema
Lipedema : LL swelling and edema due to local accumulation of excess fat under the skin of legs sparing the dorsum of the foot , exclusively in women	# most common : Phlebo-lymphedema : Lymphedema due to vascular insufficiency
Dorsum of the foot is spared	Dorsum of the foot Not spared
Bilateral غالباً	Obstructive lymphedema usually unilateral (95% of cases)
Non pitting edema bilaterally	Non pitting edema bilaterally or unilaterally
	
<p style="text-align: center;">علاجها Liposuction شفط الدهون مع التخسيس لو المريضه obese <u>Not diuretics</u></p>	

Lymphedema أسباب

Inflammation

- * Filariasis
- * Recurrent cellulitis.

Obstruction of lymphatics

- prostate cancer in men
- Lymphoma in women
- Pelvic tumor
- Major pelvic surgery

وده علامات مميزه لل

Lymphedema due to chronic venous insufficiency

دى غالبا بتكون مصاحبه ب Skin changes

بيحصل التهاب فى الجلد والطبقات الللى تحته
وبيعمل تصلب وتحجر فى الجلد واسمه

Lipodermatosclerosis

بييجى فى الاول Acute

وبعدين بيحصل تليف تحت الجلد فيتحول الى

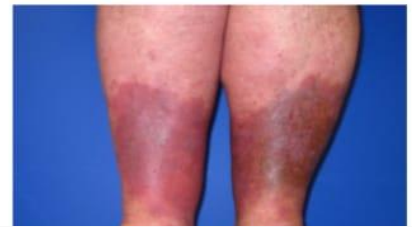
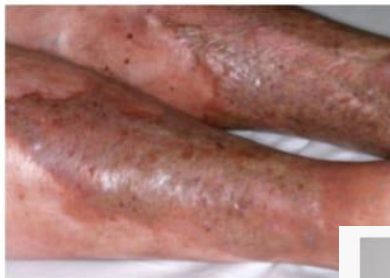Chronic lipodermatosclerosis

فيخلى الجزء الللى كان ملتهب ولم حصل فى
ضمور وبقي ال Size

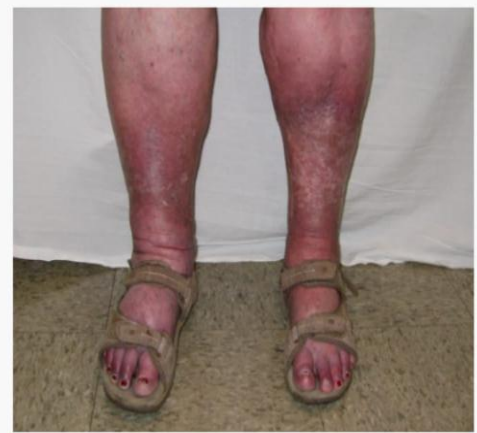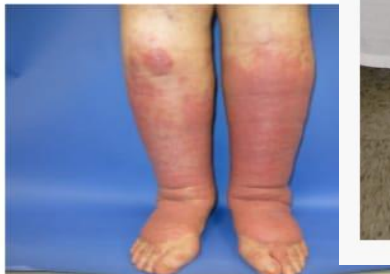بتاعه اصغر من الطبيعى وبيسمو المنظر ده

Inverted champagne

Acute lipodermatosclerosis



Acute lipodermatosclerosis



Acute lipodermatosclerosis

كمان هنلاحظ تحول لون الجلد للون البنى ومعاه Pigmentation

وده Hemosiderin staining

وسببه ان بسبب الالتهاب بعض ال

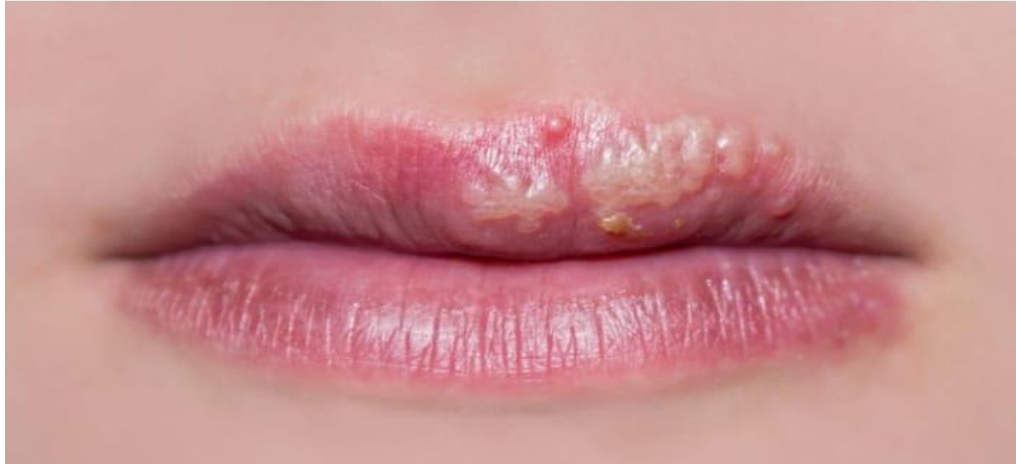RBC's --> rupture under the skin --> release of Hb --> iron --> brown stain

فكر معنا!!!

In your clinic 3 patients

Patient 1:

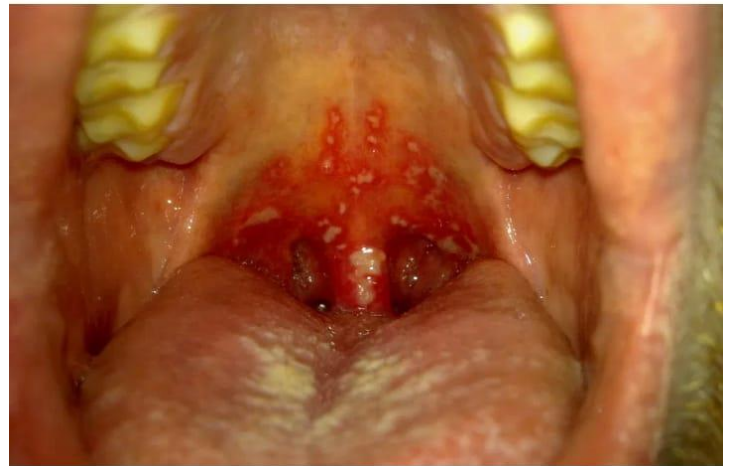Complains of lesion affecting his lip as shown below



Patient 2:

Complains of Sore throat, gum pain, fever (38) and anorexia

You examined his mouth and Photo shown here



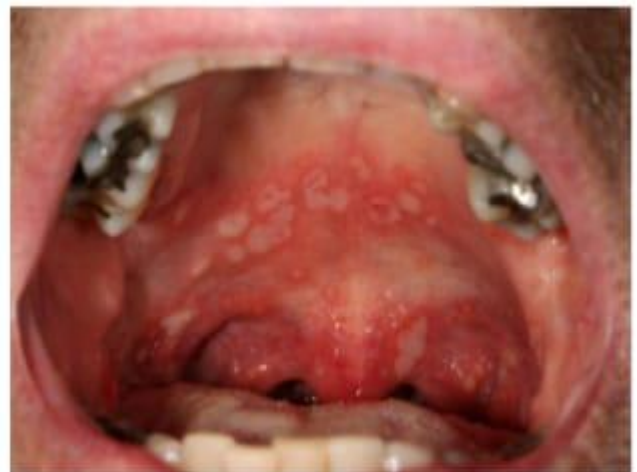Patient 3:

Complains of sore throat, fever: 38.6

Headache, myalgia,

You examined his mouth

Shown here



Patient 1:

السهم بيشاور على
Vesicles
اسمها
cold sores

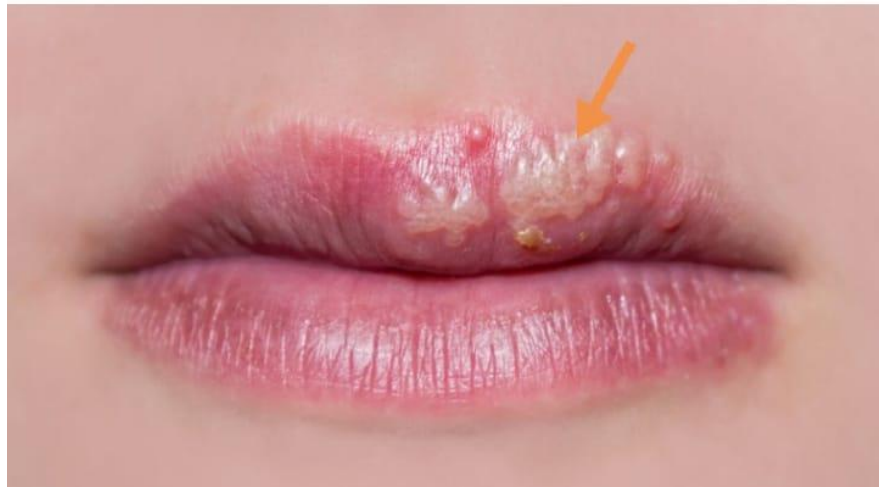Cause: Herpes simplex virus

Occur after URTI

Occasionally with pneumococcal
pneumonia

Benign condition /self-limited
disease

Ttt: topical Acyclovir



Patient 2:

الاسهم بتشاور ع

Vesicles on uvulua & oropharynx

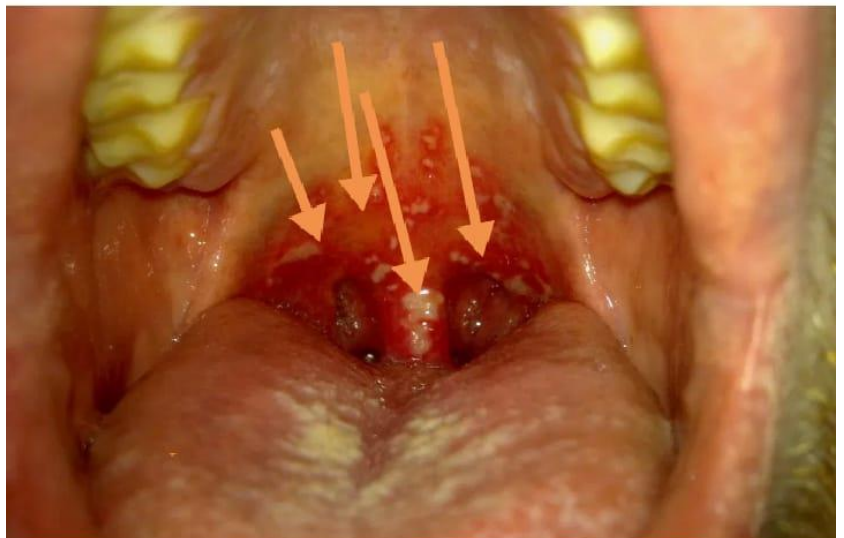
والمريض بيشتكى من
Painful gums
بس مش ظاهره فى الصورة

DX: Herpetic gingivostomatitis

Ttt : Mouth wash

Topical analgesic spray (BB C spray)

Oral Acyclovir



Patient 3:

الاسهم بتشاور على

Vesicles at the junction between hard & soft
palate

دى اسمها

Herpangia

سببها

Coxsackie virus

Self-limited disease

العلاج

Topical analgesic spray

+

Mouth wash

